



# Morphology combined with ancillary techniques: An algorithm approach for thyroid nodules

E. D. Rossi<sup>1</sup>  | M. Martini<sup>1</sup> | S. Capodimonti<sup>1</sup> | T. Cenci<sup>1</sup> | M. Bilotta<sup>1</sup> |  
F. Pierconti<sup>1</sup> | A. Pontecorvi<sup>2</sup> | C. P. Lombardi<sup>3</sup> | G. Fadda<sup>1</sup>  | L. M. Larocca<sup>1</sup>

<sup>1</sup>Division of Anatomic Pathology and Histology, Fondazione Policlinico Universitario "Agostino Gemelli" School of Medicine, Rome, Italy

<sup>2</sup>Division of Endocrinology, Fondazione Policlinico Universitario "Agostino Gemelli" School of Medicine, Rome, Italy

<sup>3</sup>Division of Endocrine-Surgery, Fondazione Policlinico Universitario "Agostino Gemelli" School of Medicine, Rome, Italy

## Correspondence

Esther Rossi, Division of Anatomic Pathology and Histology, Università Cattolica del Sacro Cuore, "Agostino Gemelli" School of Medicine, Rome, Italy.  
Email: esther.rossi@policlinicogemelli.it

**Introduction:** Several authors have underlined the limits of morphological analysis mostly in the diagnosis of follicular neoplasms (FN). The application of ancillary techniques, including immunocytochemistry (ICC) and molecular testing, contributes to a better definition of the risk of malignancy (ROM) and management of FN. According to literature, the application of models, including the evaluation of ICC, somatic mutations (ie,  $BRAF^{V600E}$ ), micro RNA analysis is proposed for FNs. This study discusses the validation of a diagnostic algorithm in FN with a special focus on the role of morphology then followed by ancillary techniques.

**Methods:** From June 2014 to January 2016, we enrolled 37 FNs with histological follow-up. In the same reference period, 20 benign nodules and 20 positive for malignancy were selected as control. ICC,  $BRAF^{V600E}$  mutation and miR-375 were carried out on LBC.

**Results:** The 37 FNs included 14 atypia of undetermined significance/follicular lesion of undetermined significance and 23 FN. Specifically, atypia of undetermined significance/follicular lesion of undetermined significance resulted in three goitres, 10 follicular adenomas and one NIFTP whereas FN/suspicious for FN by seven follicular adenomas and 16 malignancies (nine non-invasive follicular thyroid neoplasms with papillary-like nuclear features, two invasive follicular variant of papillary thyroid carcinoma [PTC] and five PTC). The 20 positive for malignancy samples included two invasive follicular variant of PTC, 16 PTCs and two medullary carcinomas. The morphological features of  $BRAF^{V600E}$  mutation (nuclear features of PTC and moderate/abundant eosinophilic cytoplasm) were associated with 100% ROM. In the wild type cases, ROM was 83.3% in presence of a concordant positive ICC panel whilst significantly lower (10.5%) in a negative concordant ICC. High expression values of MirR-375 provided 100% ROM.

**Conclusions:** The adoption of an algorithm might represent the best choice for the correct diagnosis of FNs. The morphological detection of  $BRAF^{V600E}$  represents the first step for the identification of malignant FNs. A significant reduction of unnecessary thyroidectomies is the goal of this application.

## KEYWORDS

$BRAF$  mutation, immunocytochemistry, molecular testing, plump cells, thyroid malignancies, thyroid nodules

## 1 | INTRODUCTION

Thyroid cancer represents the most common endocrine malignancy with a worldwide incidence of 2% per year in the general population. According to the literature, papillary thyroid carcinoma (PTC) is the most frequent carcinoma, accounting for 80%-85% of all the thyroid malignancies.<sup>1-4</sup> An accurate cytological evaluation of thyroid nodules constitutes the first diagnostic step for the definition of their nature.<sup>1,5</sup> In fact, in most patients with thyroid nodules, the clinical and/or surgical management of these lesions begin with a cytological evaluation. The difficulties in reproducibility, especially in the *grey zone* of the indeterminate category, may result in highly variable diagnoses, which ultimately cause significant discrepancies in their management for both clinicians and patients.<sup>6-11</sup> Equally importantly, the indeterminate category includes both benign and malignant entities which raise discussions as highlighted by the large number of publications evaluating the diagnostic efficacy, risk of malignancy and implications for their correct management. The current diagnostic terminology, according to the Bethesda System of Reporting Thyroid Cytopathology (TBSRTC), includes three different subcategories for indeterminate lesions: (1) atypia of undetermined significance (AUS)/follicular lesion of undetermined significances (FLUS); (2) follicular neoplasm (FN)/suspect for FN (SFN); and (3) suspicious for malignancy (SM).<sup>5</sup> Among these, AUS/FLUS represents one of the most problematic categories because it is composed of a heterogeneous group of lesions showing a malignant rate between that of diagnostic category II (benign) and IV (FN/SFN). The need for a conclusive cytological interpretation of these indeterminate lesions led to the conclusion that the morphological limits might be overcome by the useful application of ancillary techniques (eg, immunocytochemistry [ICC] and mutational analysis). In fact, these techniques are likely to empower the diagnostic accuracy of FNAC and to allow a more accurate prediction of the nature of the lesions.<sup>12-22</sup> Several studies have underlined the role of either single or multiple markers for the category of indeterminate lesions; this is mainly due to the high specificity of some of these markers so that their expression can be considered as a strong evidence of cancer.<sup>12-30</sup> In fact, these additional techniques help to refine the cytological evaluation leading to a reduction of the number of useless total thyroidectomies and to the definition of the most suitable tailored clinical and/or surgical strategies.

Consequently, the revision of the American Thyroid Association clinical management guidelines suggested the performance of ancillary techniques in the evaluation of indeterminate lesions.<sup>23-25</sup> Nonetheless, the definition of a uniform sequential approach of ancillary techniques is still far from having been accepted and/or defined. Although some studies proved the high sensitivity but low specificity of ICC, numerous authors have demonstrated either the high specificity of somatic mutations mostly including *BRAF*<sup>V600E</sup> and *RAS* mutations, *RET/PTC* rearrangements or the recent acknowledgement of the role of micro-RNAs (miRNAs).<sup>12,13,15-22,26-40</sup> In recent years, some authors have proposed that the adoption of ancillary

techniques in an algorithm tree might represent the best solution for the indeterminate lesions. Nonetheless, the recognition that, in samples positive for malignancy (PM), specific morphological features are associated with somatic mutations (eg, *BRAF*<sup>V600E</sup>) emphasised the pivotal and crucial role of morphology in the evaluation and interpretation of an algorithm-combined approach.<sup>41</sup>

Given that, in the current study we analysed a series of thyroid follicular proliferations applying a systematic algorithm approach composed of morphology plus different ancillary techniques on LBC.

## 2 | MATERIAL AND METHODS

In the current evaluation we combined the results of morphological evaluation with an ICC panel (including HBME-1 and galectin-3), *BRAF*<sup>V600E</sup> mutation and miR-375 analysis on a series of 37 indeterminate lesions. Specifically, we included all the 37 consecutive prospective FN samples with histological follow-up in the period between June 2014 and January 2016. In the same reference period, we analysed and compared the cyto-histology of all PTCs and all benign nodules (BN) with histological outcome. However, for statistical purposes we use a cohort series including 20 BN and 20 PM. A subset of cases with the application of miRNA-375 was also discussed in a previous publication.<sup>37</sup>

All the cases were recorded in the Division of Anatomic Pathology and Histology of the Catholic University, *Agostino Gemelli* Hospital of Rome (Italy). All FNAC was carried out under ultrasonographic guidance (US), mostly by surgeons and endocrinologists and processed with LBC, Thin Prep 5000™ method (Hologic Co., Marlborough, MA, USA). The lower limit for cytological adequacy of each sample was established according to the Bethesda and British RCPATH classification schemes; the lower limit for the adequacy for each sample was established in six groups of thyroid follicular epithelial cells within the submitted slide and each of these groups with at least 10 well-visualised epithelial cells.<sup>5,42</sup>

Our patients were studied with US during their thyroid check-up performed in the Centre for Thyroid Diseases of our hospital. The series included 31 male and 46 female patients with a median age of 30 years (age range 19-76 years, median age 44 years) and size ranging from 0.5 to 6 cm (Table 1). All the lesions smaller than 1 cm were recognised during the US evaluation. All the incidental carcinomas were excluded from the series.

All aspirations (usually two passes for each lesion) were performed with 25-27 gauge needles; no rapid on-site assessment of the adequacy of the material was done. All patients had been appropriately informed regarding the use of LBC method for processing their samples and a written informed consent was signed. Our study followed the tenants of the Declaration of Helsinki and we received the institutional (Catholic University) ethical approval for the study.

The technical steps for liquid based preparations have been clearly described in previous papers of our group.<sup>14,30,36,39-41,43</sup> The

**TABLE 1** Clinicopathological data of the entire series of 77 thyroid lesions with cyto-histological correlation

	BN (20 cases)	Indeterminate lesions (37 cases)		PM (20 cases)
		AUS/FLUS	FN/SFN	
Male	8	6	8	9
Female	12	8	15	11
Age (years), range (median)	19-70 (25.5)	20-73 (26.5)		24-72 (48)
Size				
≤2 cm <sup>a</sup>	9	8	12	14
>2 cm <sup>b</sup>	11	6	11	6
Histology				
Goitre	20	3	0	0
FA	0	10	7	0
PTC	0	0	5	16
FVPC <sup>c</sup>	0	1	11	2
MTC	0	0	0	2

AUS/FLUS, Atypia of undetermined significance/Follicular lesion with undetermined significance; BN, Benign Nodule; FA, follicular adenoma; FN, follicular neoplasm; FVPC, follicular variant of PTC; MTC, Medullary thyroid carcinoma; PM, Positive for malignancy; PTC, Papillary thyroid carcinoma.

<sup>a</sup>Size between 0.5 and 2 cm.

<sup>b</sup>cases between 2 and 6 cm;

<sup>c</sup>Including both encapsulate FVPC and I-FVPC.

resulting slide was fixed in 95% methanol and stained with Papanicolaou while the remaining material was stored in the PreservCyt™ solution to be possibly used for the preparation of additional slides for further investigations (including both ICC and molecular analysis).

The cytological cases were classified and diagnosed according to the New Italian Working Group SIAPEC-IAP classification.<sup>44</sup> The above mentioned categories are defined as follows: TIR1: inadequate and TIR1C: cystic-haemorrhagic lesions; TIR2: BN; TIR3A: FN (low-risk indeterminate lesions); TIR3B: FN (high-risk indeterminate lesions); TIR4: SM; TIR5: PM. The definition of FN included both TIR3A and TIR3B. For the reader's convenience and with the exclusion of the definitions of TIR3A (increased cellularity with numerous microfollicular structures in a background of poor colloid amount) and TIR3B (characterised by high cellularity in a monotonous and repetitive microfollicular/trabecular arrangement, with scant or absent colloid), the remaining categories did not result in any change from the previous classification system.<sup>45</sup> For this research, we ruled out all the Hürthle cell nodules (belonging to the TIR3B category) as long as their morphological features can be easily recognised on FNAC samples. Furthermore, as recently published by Dettmer et al, Hürthle cell tumours show different miRNA expression patterns allowing to discriminate between Hürthle cell adenomas and carcinomas, which was not the goal of the current project.<sup>28</sup>

Although the cytological cases were diagnosed according to the New Italian Working Group SIAPEC-IAP classification, the majority

of categories overlapped with the diagnoses adopted by TBSRTC.<sup>5</sup> Specifically, the cytological diagnoses of BNs, SMs and PMs share identical features in both systems, whilst TIR3As correspond to AUS/FLUSs and TIR3Bs to FN.<sup>44</sup> All the samples were re-evaluated and classified according to TBSRTC. The analysis was conducted using TBSRTC terminology.

Our global cytological series included the following distribution of diagnoses during the reference period: 6.8% non-diagnostic plus cystic cases; 80.7% BN; 3% AUS-FLUS; 5.4% FN-SFN; 1.8% SM and 2.3% PM. All the cytological and histological samples were reviewed by two expert pathologists (E.D.R. and G.F.) and those cases whose interpretation was equivocal were submitted to the diagnostic judgment of the other pathologists until a final agreement was achieved.

## 2.1 | ICC analysis

Concerning the ICC analysis, we tested HBME-1 and galectin-3. Specifically, ICC was run on LBC specimens using the standard protocol reported in our previous papers.<sup>30,36,39-41,43</sup> The percentage of disease cells for the ICC was evaluated at 30% in all the LBC samples. Positivity was assessed for each cytological case when at least 50% of the cells demonstrated strong cytoplasm positivity. To avoid false negative and/or false positive yields, the arbitrary 50% ICC cut-off value was also established based on the histological diagnoses and samples. The positivity of each case was defined only when a concomitant positive expression of the two immunomarkers was detected. galectin-3 displayed cytoplasm staining; HBME-1 staining was within the cytoplasm with membranous and luminal accentuation. Positive controls were represented by mesothelioma cells for HBME-1 and histiocytes for galectin-3, whereas a negative control was defined by lymphocytes identified in most thyroid slides. Despite the well-known and invaluable role of cell blocks, our decision to apply ICC to LBC was mainly based on two reasons: (1) our long-standing experience with ICC on LBC; and (2) according to our personal experience with ICC on cell blocks, we reported some cases with contradictory results (false-positive or false-negative findings) that were not encountered on LBC.<sup>30,36,39-41,43,46</sup>

## 2.2 | Molecular analysis of BRAF mutation

DNA was extracted from material stored in Preserve-Cyt® solution (Hologic, Marlborough, MA, USA) and from paraffin embedded tissues as previously described.<sup>20</sup> Sensitivity of this method states at 15% in our laboratory.<sup>47</sup> The percentage of disease specific cells for molecular analysis was at least 50% in all the LBC samples. The BRAF<sup>V600E</sup> mutational analysis was also performed on DNA extracted by surgical specimens containing at least 70% of the tumour. The concordance of mutational analysis between the surgical and LBC samples was 100%. The molecular analysis was carried out on the material stored in the PreservCyt solution with 2 mL remaining material eluted in 5 mL of PreservCyt solution.

## 2.3 | Histology

All surgical specimens were fixed in 10% buffered formaldehyde, embedded in paraffin and the 5- $\mu$ m thick microtome sections were stained with haematoxylin-eosin. The lesions were all included for histological evaluation. All the peri-thyroidal adipose tissue was embedded and examined for lymph node research. The diagnosis of PTC was based on the presence of true papillary structures and the distinctive nuclear features whereas the diagnosis of FVPC relied upon the detection of almost entire follicular architecture and the nuclear features of PTC in multiple foci. All the cases were classified according to the seventh edition of the tumour-node-metastasis staging system recommended by the American Joint Commission on Cancer.<sup>48</sup> The histological diagnosis of encapsulated FVPC or non-invasive follicular thyroid neoplasm with papillary-like nuclear features (NIFTP) was rendered according to the criteria described in the recent paper by Nikiforov et al.<sup>49</sup> Encapsulated tumours with either lympho-vascular invasion (within the capsule or beyond) or capsular penetration were diagnosed as invasive FVPCs (I-FVPC). The diagnosis of follicular adenoma (FA) was based on the evidence of a capsulated nodular lesion with typical follicular cells. The diagnosis of goitre was based on the typical benign nodular findings with micro-medial follicular structures without any cellular and/or architectural atypia.

## 2.4 | Molecular analysis of miR-375

Total RNA was isolated with miRNeasy Mini Kit (Qiagen, Milan, Italy) from our LBC series following the manufacturer's instructions. One hundred ng of total RNA was reverse transcribed to cDNA using ImProm™ Reverse Transcription System (Promega, Milan Italy) with 2  $\mu$ L (1  $\mu$ M) stem-loop RT primers for miR-375 and U6 snRNA.

U6 snRNA was used as an endogenous control. The mixture was incubated in a final volume of 20  $\mu$ L at 75°C for 5 minutes, 4°C for 3 minutes, 25°C for 5 minutes, 42°C for 60 minutes and 70°C for 15 minutes, and then held at 12°C. After reverse transcription (RT), real-time polymerase chain reaction (PCR) was performed using KAPA SYBR FAST Universal qPCR Kit (KAPA BIOSYSTEMS, Milan, Italy) on CFX96 Real Time System (Biorad, Milan, Italy), according to the user's manual. Briefly, quantitative PCR of biological samples was done in 20  $\mu$ L total volume with 2  $\mu$ L RT products, 10  $\mu$ L of 2 $\times$  KAPA SYBR FAST Universal qPCR Kit, 250 nM of each primer. All reactions were run in triplicate. The specificity of each PCR product was validated by melting curve analysis at the end of PCR cycles. Samples were excluded if the PCR melt curves suggested multiple products or triplicates were inconsistent.

MiRNA expression was normalised to that of the U6 snRNA using the  $2^{-\Delta\Delta Ct}$  method. The primers used were: LRTmiR-375: 5'-GTCGTATCCAGTGCAGGGTCCGAGGTATTCGACTGGATACGACTCACGC-3'; LRT-U6 snRNA: 5'-AAAATATGGAACGCTTCACGATTTG-3'; miR-375 S 5'-CGTTTGTTCGTTCCGGCTC-3'; miR-375 AS 5'-GTGCAGGGTCCGAGGT-3'; U6snRNA S 5'-CTCGCTTCGGCAGCATATACT-3'; U6snRNA AS 5'-ACGCTTCACGAATTTGCGTGTC-3'.

## 2.5 | Statistical analysis

Statistical analysis was performed using GraphPad-Prism 5 software (Graph Pad Software, San Diego, CA) and MedCalc version 10.2.0.0 (MedCalc Software, Mariakerke, Belgium). Statistical comparison of continuous variables was performed by the Mann-Whitney U-test or paired t-test, as appropriate. Comparison of categorical variables was performed by chi-square statistic, using the Fisher's exact test. P-values less than .05 were considered statistically significant.

## 3 | RESULTS

We combined the morphological features of a series of 37 thyroid lesions with the application of  $BRAF^{V600E}$ , an ICC panel made up of HBME1 and galectin-3 and miR-375 analysis in the reference period between June 2014 and January 2016.

Table 1 shows the distribution of the clinical features for our series. Specifically, the 37 thyroid lesions were composed of 14 AUS/FLUS and 23 FN. Their histological diagnoses included three goitres, 17 FA and 17 malignancies (five classical variant of PTC and 12 FVPC). According to the new definition of NIFTP, FVPCs include 10 encapsulated FVPCs (NIFTPs) and two infiltrative FVPCs. Specifically, AUS/FLUSs were diagnosed at histology as: three goitres, 10 FA and one NIFTP; whereas FN/SFN were diagnosed as: seven FAs and 16 malignancies (nine NIFTPs, two I-FVPCs and five PTCs). Out of the number of BNs and PMs we decided to adopt a number of 40 case-control cohort including 20 BNs resulted in nodular goitres and 20 PMs which were diagnosed as 16 PTCs, two I-FVPCs and two medullary thyroid carcinomas. All the clinical and pathological features (age, sex, size) are summarised in Table 1. We did not find any statistically significant difference among the analysed parameters.

According to our recent investigation about the morphological features able to predict  $BRAF^{V600E}$  mutation in PTCs,<sup>41</sup> we identified plump cells (neoplastic cells characterised by the typical nuclear features of PTC and with moderate to abundant eosinophilic cytoplasm) and sickle-shaped nuclei in one  $BRAF^{V600E}$  mutated FN case, which was diagnosed as PTC on histology (Table 2). We found 100% correlation between the morphological features of  $BRAF^{V600E}$  mutation and the molecular yields. Our data confirmed the evidence that FVPCs have a low prevalence of  $BRAF^{V600E}$  mutation. Nonetheless, in the control group of SM/PM cases we reported seven out of 20 PMs with  $BRAF^{V600E}$  mutation (six PTCs and one I-FVPC, 35%). The mutational analysis of  $BRAF^{V600E}$  showed 23.5% sensitivity, 100% specificity and positive predictive value (PPV), 47% negative predictive value (NPV) and 54.4% diagnostic accuracy.

All 77 cases were analysed with an ICC panel made up of HBME-1 and galectin-3. Our 20 BNs showed a negative concordant ICC panel whilst our 20 PMs included 16 cases with a positive concordant ICC panel and four cases with a discordant ICC panel characterised by three cases with HBME-1 positivity and galectin-3

**TABLE 2** *BRAF*<sup>V600E</sup> mutational analysis in AUS/FLUS (TIR3A), FN (TIR3B), SM (TIR4) and PMs (TIR5)

	Cytology			Histology			
	AUS/FLUS	FN/SFN	SM/ PM	FA	PTC	FVPC <sup>a</sup>	MTC
WT	14	22	13	20	14	13	2
<i>BRAF</i> <sup>V600E</sup>	0	1	7	0	7	1	0

AUS/FLUS (TIR3A), Atypia of undetermined significance/Follicular lesion with undetermined significance; BN, benign nodule; FA, follicular adenoma; FN (TIR3B), follicular neoplasm; FVPC, follicular variant of PTC; MCT: medullary thyroid carcinoma; PM (TIR5): positive for malignancy; PTC: papillary thyroid carcinoma; SM: suspicious for malignancy (TIR4).

<sup>a</sup>Including both encapsulated and invasive FVPCs.

**TABLE 3** Immunocytochemistry in our 37 indeterminate lesions (AUS/FLUS[TIR3A] and FN/SFN[TIR3B])

ICC	Cytology		Histology			
	AUS/FLUS	FN/SFN	FA	PTC	FVPC <sup>a</sup>	NIFTP
H+/G+	2	16	3	5	10	8
H-/G-	12	3	13	0	2	2
H+/G-	0	0	0	0	0	0
H-/G+	0	4	4	0	0	0

AUS/FLUS, Atypia of undetermined significance/Follicular lesion with undetermined significance; BN, benign nodule; FA, follicular adenoma; FN, follicular neoplasm; FVPC, follicular variant of PTC; G, galectin-3; H, HBME-1; PM, positive for malignancy; PTC, papillary thyroid carcinoma.

<sup>a</sup>Including both encapsulated and invasive FVPCs (a specific column for NIFTP was also added).

negativity and one case with HBME-1 negativity and galectin-3 positivity.

The results of ICC staining for the 37 FNs are reported in Table 3. The majority of AUS/FLUS and FNs (15 out of 18, 83.3%) with a positive concordant ICC panel had a histological diagnosis of malignancy (five PTC and 10 FVPC). By contrast, 87% of AUS/FLUS and FN/SFNs with a negative concordant ICC panel had a histological diagnosis of FA. Our data demonstrate that NIFTPs share the same ICC panel of I-FVPCs. In fact, eight out of 10 NIFTPs (80%) had a concordant positive ICC panel. Furthermore, we had five cases with a discordant panel resulting in the benign histological diagnosis of FA (Table 3). Definitely, the ICC analysis resulted in 88.2% sensitivity, 83.3% PPV, 81.2% specificity, 86.6 NPV and 75.6% diagnostic accuracy.

To evaluate miR-375 expression in the different cytological categories we set up an RT-PCR assay. After normalisation to U6 small nuclear RNA, we evaluated the miRNA amount according to the histological diagnoses. Firstly, we had an increase in the expression of miR-375 from benign to malignant lesions with a statistically significant difference ( $P < .0001$ ).

In the expression levels of miR-375, we found an increasing and statistically significant upregulation among the three categories (BN vs FN  $P = .00167$ ; BN vs PM  $P < .0001$  and FN vs PM  $P = .0002$ , respectively). Additionally, based on our previous research, we set

the same cut-off point for miRNA expression demonstrating a higher miR-375 expression in all the FNs with a malignant histology (Tables 4 and 5, Figure 1).

Our data demonstrate that miR-375 has a significant over-expression in all FNs, which results in a malignant outcome as well as in 95% of the PMs compared with BNs. We reported a significant difference ( $P = .00011$ ) between the categories of BNs and FNs (including both AUS/FLUS and FN/SFN; Table 5). Additionally, the analysis of miR-375 value for AUS/FLUS and FN/SFN demonstrated that the two subcategories had different levels of expression, respectively, below and above the cut-off value with the exception of one case diagnosed as AUS/FLUS. Interestingly, we analysed the miR-375 mean expression among the different histological diagnoses and discovered that there was an increasing expression from PTCs/FVPCs progressively up to medullary thyroid carcinomas (data not shown). Nonetheless, we did not find any statistically significant difference in the expression of miR-375 value when we compared NIFTPs and I-FVPCs (regardless of the cytological categories). However, among the group of well-differentiated cancers, I-FVPCs showed the highest value of miR-375. According to the figures, the statistical analysis for miR-375 confirmed 97.2% sensitivity, 67.2% specificity, 97.6% NPV, 63.6% PPV and 78.4% diagnostic accuracy.

Our eight *BRAF*<sup>V600E</sup> mutated (one FN and seven SM/PM) cases had higher value of miR-375 than that reported in the wild-type (wt) cases.

### 3.1 | Decision model for the classification of thyroid nodules based on the algorithm approach

The construction of an algorithm approach is likely to be a valid aid for the prediction of malignancy in thyroid nodules.<sup>50</sup> In our algorithm, we proposed that morphology is and remains the central focus of cytological evaluation. In fact, when we look at the decision tree, the first step is defined by the morphological evaluation of cytological features of thyroid nodules and the possible identification of the peculiar morphological findings of *BRAF*<sup>V600E</sup> mutation.<sup>41</sup> This first step is predictable for malignancy: if the morphological aspects associated with *BRAF*<sup>V600E</sup> mutation are recognised, then the ROM for the nodule is 100%. The recognition of these morphological features reduces the number of cases for the molecular testing with a reduction of time and costs. The second step is forwarded for the wt cases that have 40.5% ROM; in this category the application of an ICC panel showed 83.3% ROM in lesions with a concordant positive panel and a significantly lower ROM (10.5%) in those cases with a negative concordant panel. At this step, ICC analysis can be followed by the evaluation of miR-375, which is likely to provide a 100% ROM in samples with high expression (Figure 2).

The recognition of *BRAF*<sup>V600E</sup> mutation was able to identify one out of 16 malignancies (6.2%) among FNs. The following application of ICC was able to correctly define 32 (86.4%) FNs out of 37 cases whilst the final application of miR-375 was able to recognise 100% of them.

**TABLE 4** Distribution of different FNAC categories with miR-375 expression

	miR-375 expression	Cytology	Histology					
			Goitre	FA	PTC	E-FVPC	I-FVPC	MCT
Benign	<12	20 (100%)	20	0	0	0	0	0
	>12	0	0	0	0	0	0	0
FN	<12	20	3	17	0	0	0	0
	>12	17	0	0	5	10	2	0
PM	<12	1	0	0	1	0	0	0
	>12	19	0	0	15	0	2	2

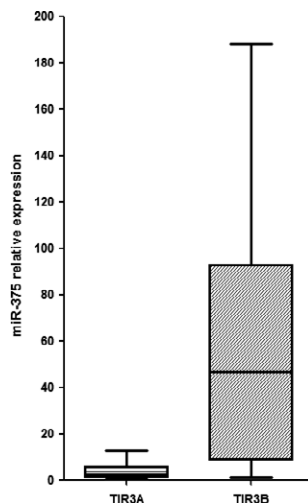
BN, benign nodules; E-FVPC, encapsulated follicular variant of papillary thyroid carcinoma; FA, follicular adenoma; FN, follicular neoplasms; I-FVPC, invasive follicular variant of papillary thyroid carcinoma; MCT, medullary thyroid carcinoma; PM, positive for malignancy; PTC, papillary thyroid carcinoma. Results are normalised to internal U6-srRNA.

**TABLE 5** The cyto-histological comparison of AUS/FLUS (TIR3A) and FN (TIR3B) with miR-375

MiR-375 expression	Cytology	Histology				
		AUS/FLUS	Goitre	FA	PTC	E-FVPC
<12	13	3	10	0	0	0
>12	1	0	0	0	1	0
	FN	Goitre	FA	PTC	NIFTPs	I-FVPC
<12	7	0	7	0	0	0
>12	15	0	0	4	9	2

BN, benign nodules; FA, follicular adenoma; FN, follicular neoplasms; FVPC, follicular variant of papillary thyroid carcinoma; MCT, medullary thyroid carcinoma; PM, positive for malignancy; PTC, papillary thyroid carcinoma.

Results are normalised to internal U6-srRNA.

**FIGURE 1** Box-plot with the statistical distribution of the expression levels of miR-375 in FNAC samples diagnosed as TIR3A (AUS/FLUS) and TIR3B (FN/SFN). Results are normalised to internal U6-srRNA

## 4 | DISCUSSION

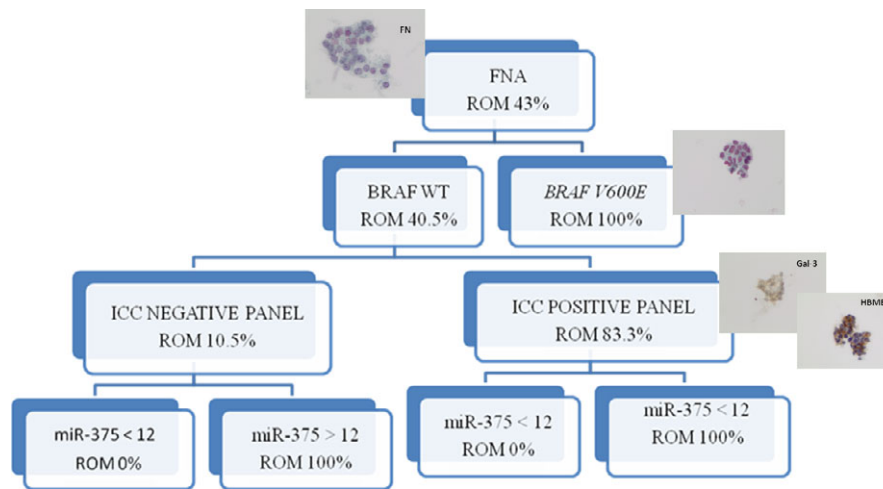
In this paper, we have evaluated the diagnostic accuracy of an algorithm model including the morphological detection of *BRAF*<sup>V600E</sup> mutation followed by the application of three different ancillary

techniques on LBC thyroid lesions combining: (1) molecular analysis of *BRAF*<sup>V600E</sup> proto-oncogene; (2) ICC made up of HBME-1 and galectin-3 immunomarkers; and (3) miR-375 analysis.

Since its initial introduction in the clinical practice, one of the primary goals of thyroid FNAC has been to distinguish benign from malignant lesions reliably but it cannot always provide a conclusive diagnosis especially for *indeterminate lesions*.<sup>5-10</sup> For decades, the painstaking role of morphology has been successfully directed to the correct diagnosis of most thyroid lesions, especially for those entities belonging to the BN and PM categories. However, whilst it has worked well for the latter categories, it is well known that FN represents a controversial cohort of lesions including both benign and malignant entities. In fact, despite the high diagnostic accuracy of morphology, several authors have highlighted that the identification of genomic alterations, more frequently associated with malignant neoplasms, represents a valid diagnostic aid in the outpatient setting to diagnose and manage the so-called *grey zone* of FN.<sup>12-22</sup> Among the ancillary techniques, several authors have suggested the application of different immunocytochemical markers, somatic mutations (ie, *BRAF* mutations, *RAS* mutations, *RET/PTC* rearrangements) and miRNAs as an additional tool for the discrimination between some benign and malignant thyroid tumours.<sup>12-22,26-40,43,50-56</sup> Specifically, HBME-1 and galectin-3 present the highest specificity and sensitivity in the identification of malignant thyroid lesions although none of the immunomarkers shows a diagnostic accuracy sufficient to be used as single specific marker of malignancy.<sup>13,30,40</sup> Cochand-Priollet et al demonstrated that an ICC panel made up of HBME-1 and Cytokeratin-19 favoured the discrimination between malignant and benign entities among FNs with sensitivity, specificity, and negative and positive predictive values of 100%, 85.2%, 100%, and 86.2%, respectively.<sup>57</sup>

Conversely, in our long-standing experience with the application of ICC (made up of HBME-1 and galectin-3) on LBC thyroid indeterminate proliferations, we assessed 81% overall diagnostic accuracy which increased to 92% in presence of a concordant positive ICC panel.<sup>30</sup>

As described in the literature, *BRAF*<sup>V600E</sup> mutation, which can be analysed in cytological samples, represents a well-known feasible diagnostic and prognostic marker in thyroid carcinoma with 45% to



**FIGURE 2** Decision algorithm for the classification of thyroid lesions and specifically indeterminate categories based on the application of  $BRAF^{V600E}$  mutation, ICC made up of galectin-3 and HBME-1 and miR-375. ROM is reported in each branch of the tree. TIR 3B (FN): follicular neoplasms. Pictures are taken at 600 $\times$ , H&E

70% prevalence mainly among the classical variant of PTCs.<sup>14,17,29,51–54,58</sup> Nonetheless, the majority of FNs does not express any specific ICC marker and do not harbour any somatic mutation including  $BRAF^{V600E}$ , so that these ancillary techniques do not concretely contribute to the correct diagnosis of a significant percentage of FNs.<sup>6–11,59</sup> This assessment is also based on the fact that the majority of malignant indeterminate lesions (both AUS/FLUS and FN/SFN) result in the histological diagnosis of FVPC, which does not allow for a definitive cytological diagnosis because of the difficulties in the identification of the subtle nuclear features of PTC. Not surprisingly, we confirmed low prevalence of  $BRAF^{V600E}$  mutation harboured in FVPCs and we had a global 22%  $BRAF^{V600E}$  mutation mostly associated with classical variant of PTCs (87% of our cases). The high specificity (100%) described in the current study is in agreement with the results (95%–98% specificity) obtained by Nikiforov et al, analysing a prospective study of 1056 indeterminate thyroid lesions with a seven-gene mutational panel (including both somatic mutations and rearrangements).<sup>51</sup>

Likewise, in our series, the group of indeterminate lesions showed only one  $BRAF^{V600E}$  mutated case out of 37 FNs (2.7%). This result reflects the evidence that our series of AUS/FLUS and FN/SFN included ten NIFTPs and only two I-FVPCs. Hence, we did not find any NIFTPs harbouring  $BRAF^{V600E}$  mutation, which confirms the results found by Nikiforov et al correlating NIFTPs with the lack of several mutations, lower tumourigenic potentiality and ROM.<sup>49</sup>

However, the role of  $BRAF^{V600E}$  mutation as a *rule-in* marker for malignancy, due to the high aforementioned specificity, is also counterbalanced by the low sensitivity of these molecular markers.<sup>14,29,51–55,58</sup>

Consequently, the diagnosis and management of FNs remains a vexing and open issue that warrants the evaluation and introduction of miRNA analysis on cytological material to improve some shortcomings of DNA methods.<sup>12,15,17,27,28,31,32,35,37,46,50,56,60–64</sup> In fact, several authors have reported that miRNAs play a central role in

tumour cell transformation as well as in the correlation between miRNA levels and well differentiated thyroid malignant histotypes. Specifically, a broad spectrum of thyroid neoplasms (from benign to malignant entities) were studied and linked with specific subsets of different up- and downregulated miRNAs in different entities.<sup>12,15,18,27,28,31,32,35,37,50,56,60–64</sup> Given that, several miRNAs (ie, miR221, miR-222, miR-146 analysis) were validated on cytological samples including both conventional and LBC preparations and they resulted in an upregulation among PTCs and its variants but also among indeterminate lesions.<sup>12,15,17,18,27,28,31,32,35,37,46,50,56,60–64</sup>

Even though ancillary techniques are reshaping the practice of cytology, including thyroid cytology, there has been a recent re-evaluation of the role of morphology as the guideline in the identification of morphological features linked with somatic mutations.

Recently, some authors have underlined the possibility to recognise specific morphological features harboured in histological samples of  $BRAF^{V600E}$  mutated PTC.<sup>65,66</sup> These findings included some architectural (tumour-associated stromal reaction, infiltrative tumour borders) and cellular parameters (large polygonal tumour cells, height of cell less than twice the width, features of squamoid metaplasia with homogeneous, eosinophilic, moderate to abundant cytoplasm and nuclear features of PT defined as *plump cells*). This additional *morphological* analysis was also adopted as the initial predictive aid to discriminate benign from malignant lesions also on FNACs.<sup>41</sup>

According to our findings of  $BRAF^{V600E}$  morphological features, in our algorithm approach we decided to evaluate the ROM for indeterminate lesions starting with the morphological analysis of  $BRAF^{V600E}$  mutation. Consequently, we genotyped all patients for  $BRAF^{V600E}$  mutation, immunostained for HBME-1 and galectin-3, and measured the expression of miR-375. Specifically, the reason for a combination of multiple markers was also justified by the well-known acknowledgement that none of these markers was likely to provide a 100% diagnostic accuracy as supported by the figures obtained when each ancillary technique is considered alone.<sup>67–70</sup>

Firstly, we confirmed increased expression of miR-375 among the cytological categories characterised by the lowest levels in the BNs and the highest in our malignant cohort. Our yields documented that miR-375 expression on thyroid LBC may help in suggesting a malignant outcome among FNs and it can correctly match the two subsets of lesions (AUS/FLUS and FN/SFN) with different risks of malignancy (AUS/FLUS vs FN/SFN;  $P < .0001$ ).<sup>37</sup> In detail, all the AUS/FLUS had a miR-375 value lower than the cut-off level which was associated to the malignant outcome. Moreover, also FN/SFN highlighted a correct link between miR-375 expression level and the histological outcome.

We found that both NIFTPs and I-FVPC had miR-375 values belonging to the malignant group, even though we did not report significantly different values between NIFTPs and I-FVPC. Nonetheless, our analysis revealed that NIFTPs showed an ICC panel more similar to malignant lesions (80% of NIFTPs) than benign entities and our NIFTPs had miR-375 values higher than the cut-off to discriminate between benign and malignant lesions. We are aware that additional studies and larger series are necessary for a correct discrimination between NIFTPs and I-FVPCs.

As shown in Figure 2, the ROM decreased from 43% to 40.5% in BRAF wild type cases, with a significant 10.5% ROM in cases with concordant negative ICC panel and 0% ROM for those cases showing low expression levels of miR-375. By contrast, those cases with BRAF wt and concordant positive ICC panel showed an increased ROM (from 43% to 83.3%), which resulted in 100% ROM in presence of high miR-375 expression levels. Our yields demonstrated that the best choice is the application of all the three ancillary techniques; in fact, it correctly classified 100% of FNs as malignant and halved the number of total thyroidectomies. However, despite the result with miR-375, it should be evaluated as the final molecular testing for FNs.

Similar conclusions and significant diagnostic accuracy were also described by Paskas et al in an algorithm approach combining galectin 3, BRAF<sup>V600E</sup> and miR-221 and miR-222 for the evaluation of indeterminate lesions.<sup>50</sup>

In conclusion, despite the limitation of our study, mostly ascribed to the relatively low number of sample size and the patient selection bias, we encourage the application of an algorithm approach starting and focusing on the morphological search of the specific features linked with BRAF mutation. The proposal to wind back to the role of morphology would reduce the number of cases addressed to molecular testing, with significant savings in cost and time. In this approach we emphasised the role of our algorithm decision tree for the wild type series, which would benefit from the use of a sequential algorithm including three different ancillary techniques.

Even though the best results are achieved with the application of miR-375, the application of ICC and somatic mutations can be helpful in those laboratories in which, due to the costs, it is impossible to perform miRNA analysis in all thyroid lesions. The performance of miRNAs is likely to be carried out in those cases with consistent doubts after ICC and DNA testing. However, future

studies with more cases will define the significance and value of an algorithm approach for the clinical and/or surgical management of indeterminate lesions and the possible recognition of NIFTPs on cytology.

## CONFLICT OF INTEREST

The authors declare that they have no conflict of interest.

## AUTHORS' CONTRIBUTION

E.D.R. and L.M.L. conceived the study, participated in its design and coordination and drafted the manuscript. E.D.R., L.M.L., M.M., P.F., G.F., S.C., T.C., A.P. and C.P.L. carried out the molecular genetic studies, participated in the sequence alignment and contributed to the manuscript. S.C., M.B. and T.C. carried out and participated in the sequence alignment. E.D.R., L.M.L. and M.M., participated in the design of the study and performed the statistical analysis. All authors read and approved the final manuscript.

## DECLARATION

As reported in the material and method section, informed consent was obtained from all individual participants included in the study.

## ORCID

E. D. Rossi  <http://orcid.org/0000-0003-3819-4229>

G. Fadda  <http://orcid.org/0000-0001-9736-0544>

## REFERENCES

1. Ali S. Thyroid cytopathology: Bethesda and beyond. *Acta Cytol.* 2011;55:4-12.
2. Freitas BCG, Cerutti JM. Genetic markers differentiating follicular thyroid carcinoma from benign lesions. *Mol Cell Endocrinol.* 2010;321:77-85.
3. Sawin CT, Santisteban P, Mubarak AG, et al. History, development, anatomy. In: Braverman LE, Utiger RD, eds. *The Thyroid, a fundamental and clinical text*. USA: Lippincott Williams & Wilkins Philadelphia; 2005:3-36.
4. Sosa JA, Hanna JW, Robinson KA, Lanman LB. Increases in thyroid nodule fine-needle aspirations, operations, and diagnoses of thyroid cancer in the United States. *Surgery.* 2013;154:1420-1426.
5. Cibas ES, Ali SZ. The Bethesda System for reporting thyroid cytopathology. *Thyroid.* 2009;9:1159-1165.
6. Ho AS, Sarti EE, Jain KS, et al. Malignancy rate in thyroid nodules classified as Bethesda category III (AUS/FLUS). *Thyroid.* 2014;24:832-839.
7. Kiernan CM, Broome JT, Solozano CC. The Bethesda system for reporting thyroid cytopathology: a single-center experience over 5 years. *Ann Surg Oncol.* 2014;21:3522-3527.
8. Krane JF, Vanderlaan PA, Faquin WC, Renshaw AA. The atypia of undetermined significance/follicular lesion of undetermined significance: malignant ratio. *Cancer Cytopathol.* 2012;120:111-116.
9. Pagni F, Prada M, Goffredo P, et al. 'Indeterminate for malignancy' (TIR3/Thy3 in the Italian and British systems for classification)



- thyroid fine needle aspiration (FNA) cytology reporting: morphological criteria and clinical impact. *Cytopathology*. 2014;25:170-176.
10. Poller DN, Ibrahim AK, Cummings MH, et al. Fine-needle aspiration of the thyroid. Importance of an indeterminate diagnostic category. *Cancer Cytopathol*. 2000;90:239-244.
  11. Wang HH. Reporting thyroid fine-needle aspiration: literature review and a proposal. *Diagn Cytopathol*. 2000;34:67-76.
  12. Agretti P, Ferrarini E, Rago T, et al. MicroRNA expression profile help to distinguish benign nodules from papillary thyroid carcinomas starting from cells of fine needle aspiration. *Eur J Endocrinol*. 2012;167:393-400.
  13. Correia-Rodrigues HG, Nogueira DPA, Adan LFF. Use of molecular markers in samples obtained from preoperative aspiration of thyroid. *Endocr J* 2012; 59: 417-424.
  14. Fadda G, Rossi ED. Liquid based cytology in fine needle aspiration biopsies of the thyroid gland. *Acta Cytol*. 2011;55:389-400.
  15. Keutgen XM, Filicori F, Crowley MJ, et al. A panel of four miRNAs accurately differentiates malignant from benign indeterminate thyroid lesions on fine needle aspiration. *Clin Cancer Res*. 2012;18:2032-2038.
  16. Mazeh H, Levy Y, Mizrahi I, et al. Differentiating benign from malignant thyroid nodules using micro ribonucleic acid amplification in residual cells obtained by fine needle aspiration biopsy. *J Surg Res*. 2013;180:216-221.
  17. Nikiforov YE, Steward DL, Robinson-Smith TM, et al. Molecular testing for mutations in improving the fine needle aspiration diagnosis of thyroid nodules. *J Clin Endocrinol Metab*. 2009;94:2092-2098.
  18. Nikiforova MN, Chiosea SI, Nikiforov YE. MicroRNA expression profiles in thyroid microRNAs in thyroid fine needle aspiration biopsy samples. *Thyroid*. 2012;22:285-291.
  19. Nikiforova MN, Nikiforov Y. Molecular diagnostics and predictors in thyroid cancer. *Thyroid*. 2009;19:1351-1361.
  20. Rossi ED, Martini M, Capodimonti S, et al. BRAF (v600e) mutation analysis on LBC-processed aspiration biopsies predicts bilaterality and nodal involvement in papillary thyroid microcarcinoma. *Cancer Cytopathol*. 2013;121:291-297.
  21. Shen R, Liyanarachchi S, Li W, et al. MicroRNA signature in thyroid fine needle aspiration cytology applied to "atypia of undetermined significance" cases. *Thyroid*. 2012;22:9-16.
  22. Zhang Y, Zhong Q, Chen X, Fang J, Huang Z. Diagnostic value of microRNAs in discriminating malignant thyroid nodules from benign ones on fine needle aspiration samples. *Tumor Biol*. 2014;35:9343-9353.
  23. Cooper DS, Doherty GM, Haugen BR, et al. Revised management guidelines for patients with thyroid nodules and differentiated thyroid cancer. *Thyroid*. 2009;19:1167-1214.
  24. Ferris RL, Baloch ZW, Bernet V, et al. American Thyroid Association Statement on surgical application of molecular profiling for thyroid nodules: current impact on perioperative decision making. *Thyroid*. 2015;25:760-768.
  25. Haugen BR, Alexander E, Bible KC, et al. American Thyroid Association (ATA) Guidelines Taskforce on Thyroid Nodules and Differentiated Thyroid Cancer American Thyroid Association management guidelines for adult patients with thyroid nodules and differentiated thyroid cancer. *Thyroid*. 2015;26:1-133.
  26. Chen YT, Kitabayashi N, Zhou XK, et al. MicroRNA analysis as a potential diagnostic tool for papillary thyroid carcinoma. *Mod Pathol*. 2008;21:1139-1146.
  27. Chou CK, Chen RF, Chou FF, et al. MiR-146 is highly expressed in adult papillary thyroid carcinoma with high risk features including extrathyroidal invasion and the BRAF (V600E) mutation. *Thyroid*. 2010;20:489-494.
  28. Dettmer M, Perren A, Moch H, et al. Comprehensive microRNA expression Profiling identifies novel markers in follicular variant of papillary thyroid carcinoma. *Thyroid*. 2013;23:1383-1389.
  29. Diggans J, Kim SY, Hu Z, et al. Machine learning from concept to clinic: reliable detection of BRAFV600E DNA mutations in thyroid nodules using high-dimensional RNA expression data. *Pac Symp Biocomput*. 2015;20:371-382.
  30. Fadda G, Rossi ED, Raffaelli M, et al. Follicular thyroid neoplasms can be classified as low and high risk according to HBME-1 and galectin 3 expression on liquid based fine needle cytology. *Eur J Endocrinol*. 2011;165:447-453.
  31. Hudson J, Duncavage E, Tamburrino A, et al. Over expression of miR-10a and miR-375 and down regulation of YAP1 in medullary thyroid carcinoma. *Exp Mol Pathol*. 2013;95:62-67.
  32. Jikuzono T, Kawamoto M, Yoshitake H, et al. The miR-221/222 cluster, miR-10B and Mir-92a are highly upregulated in metastatic minimally invasive follicular thyroid carcinoma. *Int J Oncol*. 2013;42:1858-1868.
  33. Longatto-Filho A, Goncalves AE, Martinho O, et al. Liquid based cytology in DNA-based molecular research. *Anal Quant Cytol Histol*. 2009;31:395-400.
  34. Mazeh H, Mizrahi I, Halle D, et al. Development of a microRNA-based molecular assay for the detection of papillary thyroid carcinoma in aspiration biopsy samples. *Thyroid*. 2011;21: 111-118.
  35. Pallante P, Visone R, Ferracin M, et al. MicroRNA deregulation in human thyroid papillary carcinomas. *Endocr Relat Cancer*. 2006;13:497-508.
  36. Rossi ED, Martini M, Capodimonti S, et al. Analysis of immunocytochemical and molecular BRAF expression in thyroid carcinomas: a cyto-histological institutional experience. *Cancer Cytopathol*. 2014;122:527-535.
  37. Rossi ED, Martini M, Bizzarro T, et al. The evaluation of miRNAs on thyroid FNAC: the promising role of miR-375 in follicular neoplasms. *Endocrine*. 2016;54:723-732.
  38. Xing M. Braf mutation in papillary thyroid cancer: pathogenic role, molecular bases and clinical implications. *Endocr Rev*. 2007;28:742-762.
  39. Rossi ED, Mulè A, Russo RM, Pierconti F, Fadda G. Application of liquid based preparation to non-gynecological exfoliative cytology. *Pathologica*. 2008;100:461-465.
  40. Rossi ED, Raffaelli M, Minimo C, et al. Immunocytochemical evaluation of thyroid neoplasms on thin-layer smears from fine-needle aspiration biopsies. *Cancer*. 2005;105:87-95.
  41. Rossi ED, Bizzarro T, Martini M, et al. Morphological parameters able to predict BRAFV600E mutated malignancies on thyroid fine-needle aspiration cytology: one institutional experience. *Cancer Cytopathol*. 2014;122:883-891.
  42. British Thyroid Association, Royal College of Physicians. *Guidelines for the management of thyroid cancer*. 3rd edn. London: Royal College of Physicians; 2014.
  43. Rossi ED, Martini M, Capodimonti S, et al. Diagnostic and prognostic value of immunocytochemistry and BRAF mutation analysis on liquid based biopsies of thyroid neoplasms suspicious for carcinoma. *Eur J Endocrin*. 2014;168:853-859.
  44. Nardi F, Basolo F, Crescenzi A, et al. Italian consensus for the classification and reporting of thyroid cytology. *J Endocrinol Invest*. 2014;37:593-599.
  45. Fadda G, Basolo F, Bondi A, et al. Cytological classification of thyroid nodules. *Pathologica*. 2012;102:405-408.
  46. Rossi ED, Bizzarro T, Martini M, et al. Cytopathology of follicular cell nodules. *Adv Anat Pathol*. 2017;24:45-55.
  47. Martini M, Teofili L, Cenci T, et al. A novel heterozygous HIF2AM535I mutation reinforces the role of oxygen sensing pathway disturbances in the pathogenesis of familial erythrocytosis. *Haematologica*. 2008;93:1068-1071.
  48. American Joint Commission on Cancer (AJCC). *Cancer Staging Atlas*. 2nd edn. New York: Springer-Verlag; 2013.

49. Nikiforov YE, Sethala RR, Tallini G, et al. Nomenclature revision for encapsulated follicular variant of papillary thyroid carcinoma: a paradigm shift to reduce overtreatment of indolent tumors. *JAMA Oncol.* 2016;2:1023-1029.
50. Paskas S, Jankovic J, Zivalievic V, et al. Malignant risk stratification of thyroid FNA specimens with indeterminate cytology based on molecular testing. *Cancer Cytopathol.* 2015;123:471-479.
51. Nikiforov YE, Ohori P, Hodack SP, et al. Impact of mutational testing on the diagnosis and management of patients with cytologically indeterminate thyroid nodules: a prospective analysis of 1056 FNA samples. *J Clin Endocrinol Metab.* 2011;96:3390-3397.
52. Nikiforova MN, Tseng GC, Steward D, et al. MicroRNA expression profiling of thyroid tumors: biological significance and diagnostic utility. *J Clin Endocrinol Metab.* 2008;93:1600-1608.
53. Nikiforov YE, Carty SE, Chiosea SI, et al. Highly accurate diagnosis of cancer in thyroid nodules with molecular tests guide extent of thyroid surgery 767 follicular neoplasm/suspicious for a follicular neoplasm cytology by ThyroSeq v2 next-generation sequencing assay. *Cancer.* 2014;120:3627-3634.
54. Moses W, Weng J, Sansano I, et al. Molecular testing for somatic mutations improves the accuracy of thyroid fine-needle aspiration biopsy. *Surgery.* 2010;34:2589-2594.
55. Peng Y, Li C, Luo DC, et al. Expression profile and clinical significance of microRNAs in papillary thyroid carcinoma. *Molecules.* 2014;19:11586-11599.
56. Sheu SY, Grabellus F, Schwertheim S, et al. Differential miRNA expression profiles in variants of papillary thyroid carcinoma and encapsulated follicular thyroid tumors. *Br J Cancer.* 2010;102:376-382.
57. Cochand-Priollet B, Dahan H, Laloi-Michelin M, et al. Immunocytochemistry with cytokeratin 19 and HBME-1 increases the diagnostic accuracy of thyroid fine-needle aspirations. Preliminary report of 150 liquid-based fine needle aspirations with histological control. *Thyroid.* 2011;21:1067-1073.
58. Kim TH, Park YJ, Lim JA, et al. The association of the BRAFV600E mutation with prognostic factors and poor clinical outcome in papillary thyroid cancer. *Cancer.* 2012;118:1764-1773.
59. Baloch ZW, LiVolsi VA, Asa SL, et al. Diagnostic terminology and morphologic criteria for cytologic diagnosis of thyroid lesions: a synopsis of the National Cancer Institute Fine-needle aspiration state-of-science Conference. *Diagn Cytopathol.* 2008;36:425-437.
60. Tetzlaff MT, Liu A, Xu X, et al. Differential Expression of miRNAs in papillary thyroid carcinoma compared to multinodular goiter using formalin fixed paraffin embedded tissues. *Endocr Pathol.* 2007;18:163-173.
61. Weber F, Teresi RE, Broelsch CE, et al. A limited set of human microRNA is deregulated in follicular thyroid carcinoma. *J Clin Endocrinol Metab.* 2006;91:3584-3591.
62. Yan JW, Lin JS, He XX. The emerging role of miR-375 in cancer. *Int J Cancer.* 2013;135:1011-1018.
63. Yip L, Kelly L, Shuai Y, et al. 2011 MicroRNA signature distinguishes the degree of aggressiveness of papillary thyroid carcinoma. *Ann Surg Oncol.* 2011;18:2035-2041.
64. Dabbs D, Abendroth CS, Grenko RT, Wang X, Radcliffe GE. Immunocytochemistry on the Thin-Prep Processor. *Diagn Cytopathol.* 1997;17:388-392.
65. Finkelstein A, Levy GH, Hui P, Prasad A. Papillary thyroid carcinomas with and without BRAF V600E mutations are morphologically distinct. *Histopathology.* 2012;60:1052-1059.
66. Virk RK, Theoharis CGA, Prasad A, et al. Morphology predicts BRAF V600E mutation in papillary thyroid carcinoma: an interobserver reproducibility study. *Virchows Arch.* 2014;464:435-442.
67. Chen H, Izevbaye I, Chen F, Weinstein B. Recent advances in follicular variant of papillary thyroid carcinoma. *N A J Med Sci.* 2012;5:212-216.
68. Drage M, Howitt B, Krane J, Barletta J. Fine needle aspiration diagnoses of non-infiltrative, non-invasive follicular variant of papillary thyroid carcinoma. *Mod Pathol.* 2015;28:S-134A.
69. Nikiforova MN, Wald AI, Roy S, et al. 2013 Targeted next-generation sequencing panel (Thyro Seq) for detection of mutations in thyroid cancer. *J Clin Endocrinol Metab.* 2013;98:E1852-E1860.
70. Walts AE, Mirocha JM, Bose S. Follicular variant of papillary thyroid carcinoma (FVPTC): histological features, BRAF V600E mutation, and lymph node status. *J Cancer Res Clin Oncol.* 2015;141:1749-1755.

**How to cite this article:** Rossi ED, Martini M, Capodimonti S, et al. Morphology combined with ancillary techniques: An algorithm approach for thyroid nodules. *Cytopathology.* 2018;29:418-427. <https://doi.org/10.1111/cyt.12555>